Ayurvedic Management of Facioscapulohumeral Muscular Dystrophy - A Case Report

*Riddhi Bharat Lunavat, ** Subin V R

Abstract

Facioscapulohumeral muscular dystrophy (FSHD) is the 3rd most common type of muscular dystrophy with a prevalence of 4-12 in 100000. It is an inherited neuromuscular disorder causing weakness and atrophy ofthe muscles of the face, shoulder blades, upper arms,lower limb, pelvic girdle, and abdomen in an asymmetric fashion. The available management of FSHD in biomedicine is unsatisfactory. 47-year-old/Male patient presented with complaints of difficulty in walking, gradual weakness, and wasting of muscles of the shoulder girdle and right lower limb for 1 year. Based on the pattern of disease, a probable diagnosis of FSHD was made. After observing the series of events, an ayurvedic diagnosis of anyonya Aavarana of vata in mamsavaha srotas was made which resulted in Shosha(Ekanga roga) and bala hani in the presented case. Ardhamatrika and Shukra mamsala vasti followed by Marsha nasya was administered. Later patient underwent Udvartana with Shasthika choornam for 7 days. Haritakyaadi choorna virechana was given followed by Samsarjana krama with Yava-anna. Later the patient was given shilajatu rasayana for 21 days. Dhanad-nayanadi kashayam (15 ml) twice a day was given as internal medicine. The patient was assessed on criteria of walking ability, muscle power, FSHD evaluation scale, and CPK value before and after the completion of treatment and after Rasayana therapy too. He showed marked symptomatic improvement along with a reduction in CPK values, especially after Virechana and Rasayana. This case was reported to highlight the effect of Shodhana and Rasayana in muscular dystrophies.

KEY WORDS

Case report, FSHD, Anyonya Aavarana of vata, Haritakyaadi shodhana, Shilajatu rasayana

INTRODUCTION

Facioscapulohumeral muscular dystrophy (FSHD) is the 3rd most common type of muscular dystrophy with a prevalence of 4-12 in 100000[1]. It is a neuromuscular disorder characterized by progressive, asymmetrical muscle atrophy typically affecting the face, upper limb, shoulder, and laterthe lower limbs.[2] These cases are characterized by scapular winging and/or foot drop. It is an inherited disorder with an altered gene expression of DUX4 that targets the muscle cells, resulting in the production of the potentially toxic protein, building oxidative stress, and chronic inflammation.[3] However, in up to approximately 30 percent of affected individuals, there is no apparent family history of the disorder. In some of these cases, FSHD may be due to new genetic changes (mutations) that appear to occur spontaneously for unknown reasons (sporadically). Disease progression in approximately 20% ofaffected individuals may lead to severe muscle weakness that necessitates the use of a wheelchair or other mobility equipment.[4]

Genetics underlying FSHD are extremely complex, and consensus on the etiology of the disease has emerged recently, thus currently there is no effective treatment or cure exists.[5] This case is reported to provide alternative management for FSHD, highlighting the importance of Shodhana and the safety and effect of Shilajatu rasayana in FSHD. The primary focus of the management was to ameliorate the symptoms of the disease. Diagnosis of this particular case was made as Anyonya Aavarana of vata in Mamsavaha srotasa. This case was treated according to the principles of Aavarana of vata along with Mamsa gata vatawere followed.

Patient Information

A 47-year-old male patient visited the outpatient unit of VPSV AVCH on 8th November 2022 with complaints of difficulty in walking and weakness of the right lower limb developed

* PG scholar, Department of Panchakarma, VPSV Ayurveda College, Kottakkal, Kerala, India. email – riddhilunawat20@gmail.com, **Professor, Department of Panchakarma, VPSV Ayurveda College, Kottakkal, Kerala, India.

over nine months along with weakness of the right shoulder girdle and upper limb for one year with gradual onset. Daily activities like climbing the stairs, lifting weights overhead, and sitting down on the floorwere hampered. One year ago, he first experienced weakness in his right upper limb while lifting weights overhead. 9 months ago, he also noticed weakness in his rightlower limb while walking and had repetitive falls due to that. He consulted a physicianand took a course of medication in Saudi as he was working there but did not get any relief. Around that time, he noticed the thinning of muscles of the right thigh. As his condition was worsening, he came back to India and took a consultation and his probable diagnosis was made of FSHD. Genetic analysis and conservative treatments were advised to him. But he was not ready for any genetic studies and was not satisfied with the treatment given. Hence, he approached Ayurveda Hospital for further management.

He is a known case of hypertension for 4 years and is on regular medication for it. He was born to non-consanguineous parents and no positive family history of similar illness was found. Any history of recent infections was not found.

Clinical Findings

The patient was conscious and oriented with intact higher motor functions. There was an absence of pallor, edema, clubbing, and cyanosis. All cranial nerves were intact and there was no sensory impairment. Coordination tests were normal. Inspection revealed winging of the right scapula. (Figure 1). Wasting of muscles of the right lower limb and right upper limb(Proximal more than distal) and pseudohypertrophy of calf muscles on the right lower limb were observed. Muscles of affected areas are hypotonic. The muscle power of the flexor compartment of the right knee was reduced to grade 0, and that of the right ankle dorsiflexor was grade 1. Grade 4 muscle power was observed in the right shoulder and elbow. Brisk deep tendon reflexes were noted on the upper and lower limb. He had a high steppage gait due to a right foot drop.



A tenfold examination of the patient suggested his Prakriti as Pitta-pradhana vata, with Vikruti (morbidity) of Vatadosha. Along with Madhyama samhanana (~medium body constitution), Madhyamasara (~medium purest body tissue), Avara vyayam shakti (~lowermost capability to carry on physical activities), Uttam abhyavaharana and Jaranashakti (~middlemost food intake and digestive power). Mansavaha srotodushti was observed (Vitiation in micro-channels related to muscular tissues) in this patient. Srotasa Pariksha (examinations of other microchannels) revealed the normal status of other Srotasa.

Timeline (Table 1)

November 2021	1st time experienced the weakness in right shoulder girdle Unable to life weight overhead
March 2022	Repetitive falls Weakness in the right lower limb
May 2022	Weakness persisted and the patient also noticed thinning of the right thigh muscles
June 2022	Investigations started for any brain lesion and other compressive pathologies of the lumbar spine. Managed by analgesic and anti-inflammatory medications.
September 2022	Came back to India Took a consultation and a Probable diagnosis of FSHD was made. Tab. Evion 1 OD and physiotherapy were advised
November 2022	As the patient was unsatisfied with management, the patient approached VPSV AVCH for further management IP management up to virechana
December 2022	Shilajatu rasayana for 21 days.

Diagnostic Assessment

Relevant past investigations

06/06/2022

- MRI Brain – No significant neuro parenchymal abnormality.
- MRI (Lumbar Spine) –No significant disc herniation /spinal canal narrowing/ neural foraminal narrowing.
- EMG (Bilateral LL) – Bilateral tibial nerve study, Bilateral peroneal nerve study, Bilateral sural nerve study – normal

25/09/2022

- MRI (Cervical Spine) - Diffuse disc bulge and osteophytes – C3-4, C5-6, C6-7
- CPK value – 540 u/l
- Vitamin B12 – 187 pg/ml

From investigation, pathologies of cervical and lumbar nerve entrapment were ruled out. There was no sign of a cranial lesion. Increased CPK values and the extent of symptoms lead to the probable diagnosis of FSHD. Addressing the inherent nature of the disease, Beeja -bhaga dushti can beconsidered as the principal cause. As the chronicity of the disease is more than one year it was considered as Yapya vyadhi (palliative disease).[6]

Therapeutic Intervention

The treatment principle of Aavarana along with Mamsa-gata vata was considered and the protocol was framed with the intent of administering Rasayana. As the patient was not showing any Koshta gata samata lakshana[7] treatment started with Vasti chikitsa(Set of medicated enemas) followed by Nasya(nasal therapy), Udvartana(powder massage), Virechana (purgation therapy),and Rasayana (rejuvenation therapy). Details of therapeutic interventions(Table 2)and Ayurvedic medications (Table 3)are summarized below.

Table -2

Panchakarma intervention –

Procedure	Days	Medicine used	Remarks
Vasti (10/11/22)	5 days	Anuvasana – Pippalyadi tailam (75 ml) Niruha – Ardhamatrika (2 days) Shukra mamsa- bala prada vasti - 1 day	Retention of Anuvasana – over 12 hours. Lightness in the abdomen and the body Increased appetite.
Nasya (15/11/22) 	3 days	Shad Bindu tailam (1, 2, and 3 ml) Thalam - Rasna jambeeram	1st two days – Spitting of Kapha ++ Mild headache after Nasya on the 3rd day.
Udavartana (18/11/22)	7 days	Shasthika choorna	Lightness in the lower limb
Virechana (25/11/22)	1 day	Haritakyaadi shodhana	6 vegas obtained No complication was noted. Samsarjana krama – Yava bhojana – 5 days (125 gm of Yava as porridge with milk once a day, followed by Laghu aahara)

Rasayana (01/12/22)	21 days	Shuddha shilajatu choornam 3 gms + Rasna dasamooladi kashayam  	

Table 3
Internal medicine

Name of medicine	Dose	Frequency	Duration
1. Dhanad-nayanadi kashayam	15 ml kashayam + 45 ml water	BD (6 am and 6 pm)	10 days (10/11/2022 to 20/11/2022)
2. Dhanwantaram ksheer kashayam	15 ml kashayam + 30 ml boiled milk + 30 ml water	OD	After rasayana (24/11/2022 up to 3 months)
3. Ekanga veer rasa	1 tablet	HS	After rasayana (24/11/2022 up to 3 months)
4. Dhanwantaram tailam	Abhyanga	External application	After rasayana (24/11/2022 up to 3 months)

Outcomes

Outcome measurements like muscle power, FSHD evaluation scale, CPK value, and 6 min walking test were assessed before treatment, after virechana, and after follow-up (After completion of rasayana) too. Serum creatinine and serum uric acid were tested before and after administrating the Rasayana to evaluate the safety of Shilajatu rasayana.

Table 4 Outcome measurements-

Outcome measurements	BT	AT	FU
Muscle power Knee flexor Knee extensor	 0 5	 1 5	 4 5
Ankle – Dorsiflexion Plantar extension	0 5	1 5	2 5
Shoulder – Abduction Flexion	3 3	3 3	4 4
Elbow- Flexion Extension	4 5	4 5	5 5
FSHD evaluation scale	6/14	4/14	4/14
CPK values	540	260	262
6 min walking test	10 m	-	30 m
Serum creatinine	-	0.8 mg/dl	0.9 mg/dl
Uric acid	-	4.8 mg/dl	5.0 mg/dl

Discussion

Vata has a prime role in organogenesis, tissue formation, and systemic maturation throughout life. But the vitiation of Vatabrings imbalance between these processes[8]. While considering any dystrophy, the involvement of Vata ought to be taken into consideration. Out of the two main pathologies of Vata, Kevala vata prakopa was ruled out because of the absence of such Kevala vata prakopa hetu in this particular patient. In another pathology of Anyonya aavarana, the flow of Vata gets obstructed by others which leads to the continuous and progressive malfunction of Vata. As it is an inherent progressive disease, we considered Beeja-bhaga-dushti as the principal cause which further led to Mamsa-dhatwagni dushti. Apart from this, causes like Abhishyandi aahara and Diwaswapa were found in this particular patient which assisted Mamsa dhatu dushti and acted as Kha-vaigunya(Site for disease). The possible pathogenesis of the disease is shown in Figure 5

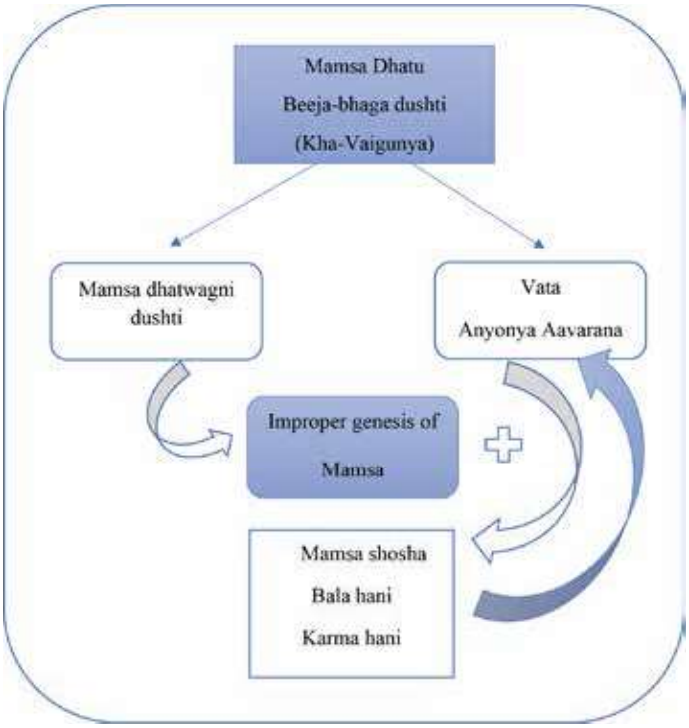

Fig. 5 – Possible pathogenesis of disease.

Considering the sequence of events and involvement of Mamsavaha srotasa and Vata, the treatment modalities like Vasti followed by Virechana were chosen considering their role in both Mamsa-gata vata and Anyonya Aavarana.

As there were no symptoms of Koshtha gata samata, for 1st two days Anuvasana was given for Pakwashaya-gata vata shamana with Pippalyadi anuvasana tailam[10], followed by Ardhamatrika vasti[11] and Shukra-mamsala vasti[12] to achieve Vata anulomana and Brumhana(Nourishment of bodily elements). As Skandha pradesha (Shoulder girdle) was also involved in pathology, Nasya (nasal instillation) of Shad-bindu tailamwhich is known for Sookshma-gamitwa and giving strength to the upper limbwas also administered in escalating dose for Urdhwajatrugata sroto-shodhana[13]. Udvartana(Powder massage) was chosen for its properties of Srotoshodhana and to provide strength to muscles (Sthirikaranam anganam)[14]. As there was no strong association with Pitta and Kapha, Shasthika choornam was used for Udvartana which has Snigdha, laghu yetBalya property[15].

Before the administration of Rasayana, virechana with Haritakyaadi choornam[16] wasintended for Koshta shodhana and to improve the bio-availability of Rasayana therapy. After Shodhana peculiar Samsarjana krama with Yava-bhojana was followed too. In this, the patient was administered Yava-anna (Yava porridge) which is also a bulk purgative to reassure Aashaya shodhana by complete evacuation of Mala.

Shilajatu rasayana is been advised in Aavarana[17]. ItsChedana property would remove the Aavarana over Mamsa dhatwagni and improveits metabolism. Shilajatu isproven to produce free radical scavenging and antioxidant[18]. It can delay the aging processes and possibly lower the risk of cell impairment and damage[19]. Shilajatu shuddhi was done in Triphala and Bhavana of Rasna-dasamooladikashayam for seven days. Three grams of this shilajatu choornam with Rasna-dasamooladi kashayam were given for twenty-one days with the same dose.

Internally Dhanad-nayanadi kashayam was given as a first line of the drug in treating Vatavyadhi. Dhanwantaram ksheer kashayam was given for Brumhana of mamsa dhatu[21]. For the same reason, Dhanwantaram tailam was selected. Ekanga-veera rasa is a compound of Kuchala (Strychnos nux-vomica L.) which is useful in imparting strength to musclefibers. Italso has the property of Brumhana and is thus helpful in alleviating the degeneration of

muscles[22].

Hence with the help of Ayurvedic treatments such as purificatory therapies, anti-inflammatory drugs, and rejuvenation therapies, we have tried to fulfill all requirements of managing progressive disorders like muscular dystrophies.

Informed Consent

Written informed consent for publication of this case study had been obtained from the patient.

References:

1. Deenen JC, Horlings CG, Verschuuren JJ, Verbeek AL, van Engelen BG. The Epidemiology of Neuromuscular Disorders: A Comprehensive Overview of the Literature. J Neuromuscul Dis. 2015;2(1):73-85. PMID: 28198707.
2. De Simone AM, et al., Facioscapulohumeral Muscular Dystrophy. Comprehensive Physiology, 2017. 7(4): p. 1229–1279.
3. Hamel, J., Tawil, R. Facioscapulohumeral Muscular Dystrophy: Update on Pathogenesis and Future Treatments. Neurotherapeutics 15, 863–871 (2018).
4. https://rarediseases.org/rare-diseases/facioscapulohumeral-muscular-dystrophy/
5. Cohen J, DeSimone A, Lek M, Lek A. Therapeutic Approaches in Facioscapulohumeral Muscular Dystrophy. Trends Mol Med. 2021 Feb;27(2):123-137. doi: 10.1016/j.molmed.2020.09.008. Epub 2020 Oct 19. PMID: 33092966; PMCID: PMC8048701.
6. Acharya Yadavaji Trikamji, editor. Agnivesha, Charaka Samhita, Ayurveda Dipika commentary by Chakrapanidatta, Chaukhambha orientalia Varanasi, 2017; Chikitsa Sthana 28/235; p.627
7. Hari Sadashiva Sastri Paradakara, editor. Ashtanga Hridaya of Vagbhata with the commentaries Sarvangasundara and Ayurvedarasayana. 10th edition. Varanasi: Chaukhamba Surbharati Prakashan; 2017; Sutra sthaan 13/23-24; p.217.
8. Acharya Yadavaji Trikamji, editor. Agnivesha, Charaka samhita, Ayurveda Dipika commentary by Chakrapanidatta, Chaukhambha orientalia Varanasi, 2008; Sutrasthana 12/8; p.79.
9. Acharya Yadavaji Trikamji, editor. Agnivesha, Charaka samhita, Ayurveda Dipika commentary by Chakrapanidatta, Chaukhambha orientalia Varanasi, 2008; Chikitsasthana 28/59; p.619
10. Acharya Yadavaji Trikamji, editor. Agnivesha, Charaka samhita, Ayurveda Dipika commentary by Chakrapanidatta, Chaukhambha orientalia Varanasi, 2008; Chikitsasthana 14/131-134; p.507
11. Tripathi Indradev, Chakradatta, Vaidyaprabha Hindi Commentary, Varanasi, Chaukhambha Sanskrit Bhavan Publication, edition 2012; Chapter 73/23-24; p.627
12. Acharya Yadavaji Trikamji, editor. Agnivesha, Charaka samhita, Ayurveda Dipika commentary by Chakrapanidatta, Chaukhambha orientalia Varanasi, 2008; Siddhi sthana 10/29; p.726
13. Mishra S, editor. Kaviraj Govind Das Sen, Bhaishajya Ratnavali,Chaukhamba Sanskriti Bhavan, Varanasi: 2013, Siro-roga adhikara, Chapter 65/81-83; p.323
14. Acharya Yadavaji Trikamji, editor. Sushruta Samhita of Sushruta with the Nibandha Sangraha commentary. 8th edition. Varanasi: Chaukhamba Orientalia; 2014, Chikitsa Sthaan 24/51; p.489
15. Acharya Yadavaji Trikamji, editor. Sushruta Samhita of Sushruta with the Nibandha Sangraha commentary. 8th edition. Varanasi: Chaukhamba Orientalia; 2014, Sutrasthaan 46/10; p.215
16. Acharya Yadavaji Trikamji, editor. Agnivesha, Charaka samhita, Ayurveda Dipika commentary by Chakrapanidatta, Chaukhambha orientalia Varanasi, 2008; Chikitsasthana 1/1/25; p.377.
17. Acharya Yadavaji Trikamji, editor. Agnivesha, Charaka samhita, Ayurveda Dipika commentary by Chakrapanidatta, Chaukhambha orientalia Varanasi, 2008; Chikitsasthana 28/242; p.672
18. Ghosal S., Lata S., Kumar Y., Gaur B. and Misra N.: Interaction of shilajit with biogenic free radicals, Indian J. Chem. B., 34, 1995, 596–602.
19. Meena H., Pandey H.K., Arya M.C. and Ahmed Z.: Shilajit: A panacea for high-altitute problems. Int. J. Ayurveda Res., 2010, 1(1), 37-40
20. Dr. Shivprasad Sharma, editor. Astanga Sangraha of Vahata or Vriddha Vagbhata, Shashilekha commentary by Indu, ChaukhambaSanskritSeries Office, Varanasi; 2019, Uttartantra 49/161; p.934
21. Hari Sadashiva Sastri Paradakara, editor. Ashtanga Hridaya of Vagbhata with the commentaries Sarvangasundara and Ayurvedarasayana. 10th edition. Varanasi: Chaukhamba Surbharati Prakashan; 2017 Sharirasthaan 2/47-52; p.383.
22. Reddy, Dr Rama Chandra. Aushadha Yoga Vijnanam; 2011 ed. Varanasi; Chaukhambha Sanskrit Bhawan; p.456